

ON AN EPIDEMIC AMONG RAINBOW TROUT IN THE
HARWAN HATCHERY, KASHMIR, DURING 1934;
WITH OBSERVATIONS ON CERTAIN RECENT
CASES OF MORTALITY.

BY

GULAM MUSTAFA MALIK, B.SC. (HONS.), B.SC.

Pisciculturist, Kashmir State.

(With 2 plates and 1 text figure).

CONTENTS.

	PAGE.
Introduction	397
Description of the material	398
Pop-eye or exophthalmia	398
Edges of the fins ragged and turned white	400
Large white marks below the gills	401
General considerations and conclusion	401
Recent cases of mortality	402
Fatty degeneration of liver	403
Malstripping	405
Summary	405
Note on the 1934 epidemic among Rainbow Trout in the Harwan Hatchery, Kashmir, by Brigadier A. Campbell Ross	405
List of references	407
Explanation of plate	408

INTRODUCTION.

At the suggestion of the Bombay Natural History Society the Zoological Survey of India was approached telegraphically in April, 1934, by the Game Warden, Jammu and Kashmir State, to suggest ways and means for avoiding the heavy mortality among Rainbow Trout in the Harwan Hatchery, Kashmir. Rai Bahadur Dr. S. L. Hora, who attended to the enquiry, suggested, as a preliminary measure, a general improvement in the sanitary conditions by the removal of any excessive plant growth and disinfection of pens with Condy's fluid. At the same time he asked for a few dead specimens for *post mortem* examination, and detailed information regarding the symptoms of the disease and the conditions under which the fish are kept in the hatchery. Three specimens of Rainbow Trout and an accompanying note (*vide infra*, pp. 405-407) from Brigadier A. Campbell Ross about the Hatchery were received. An examination of the specimens showed a number of external injuries in the case of all the three specimens, which were attributed by Dr. Hora to the spawning activities of the individuals affected. Further it was presumed that death may have resulted from fungus attack of the injured parts and its subsequent spreading to other portions of the body. However, by the 8th of May the mortality

was checked with the increase in the water supply and later almost stopped by taking out all the fish from the most affected tanks, drying the tanks and treating them with a strong solution of Condy's fluid. In view of the healthy conditions having been restored, Dr. Hora did not pursue investigations any further, but in June 1938, he very kindly placed all the material at my disposal and suggested that I should prepare a report on the epidemic of 1934 in the Harwan Hatchery. In writing this report I had the additional advantage of having worked in the Kashmir hatcheries for about two years.

I am grateful to Dr. Hora for affording me an opportunity to investigate this interesting material, and for his helpful suggestions. To Dr. Bains Prasad, Director, Zoological Survey of India, I am indebted for facilities for work in the department and for valuable criticism. I have received valuable information and material from the Game and Fisheries Division of the Forest Department, Kashmir, and for these I am obliged to the authorities concerned, particularly to Sir Peter H. Clutterbuck, Chief Conservator of Forests, to whom I am further indebted for encouragement and manifold courtesies.

DESCRIPTION OF THE MATERIAL.

The material consisted of 3 specimens of Rainbow Trout—one male, 390 mm. in standard length and 2 females, about 400 mm. in standard length. The fish died on the 20th April, 1934, and were preserved in formalin. Later, however, they were transferred to rectified spirits of wine. Owing to the preservation of the specimens it is now difficult to verify some of the diagnostic features of the disease as given by Brigadier Ross (*vide infra*, p. 406) but in the following paragraphs I have attempted to correlate the symptoms described by him with the results of the detailed *post mortem* examination of the specimens.

Pop-eye or *exophthalmia*.—Though in the preserved material the bulging eye-balls are not readily noticeable, their deep sunken condition and the presence of loose flaps of skin round the eyes indicate that, at one time, they may have protruded considerably beyond the sockets. The opacity of the eyes is distinctly marked in all the three specimens. In one of them, there are clear marks of injury to the anterior side of the right lens; while the cornea of the left eye is perforated and the lens is absent. In the other specimens both the eyes are opaque with definite marks of injury to the lens of the right eye.

According to Davis (1937, p. 65-67), the Pop-eye condition in trout results from a number of causes, which may here be considered one by one.

1. A severe infestation with the larvae of a trematode worm.

An examination of the eyes showed no evidence of trematode infestation, and, moreover, in the Harwan Hatchery there are no snails, which could serve as the principal host of any trematode. It is unlikely, therefore, that the pop-eye condition can be attributed to this cause.

2. Water supply being supersaturated by air gives rise to gas, which causes bulging of the eye-balls.

At Harwan the ponds are fed by an open snow-fed stream and, in consequence, there is no natural supersaturation of the water by air or gas.

3. Accumulation of serous fluid in the abdominal cavity and other parts of the body.

This is the common cause of pop-eye in trout, and is usually associated with the diseased condition of the kidneys which, in the affected specimens, become darker owing to the tubules being filled with crystals and casts. Heavy infestation of the kidneys with a Myxosporidian parasite also produces the same symptoms. In the specimens under report the kidneys were normal and there was no accumulation of serous fluid in the abdominal cavity.

4. Bacterial infection of the eye.

Bacterial infection, though not well established, is usually seasonal and the mortality due to this cause is confined to spring and early summer. It affects chiefly the adult fish. The usual symptom is the appearance of bubbles or blisters on the surface of the body usually above the lateral line. No such blisters, however, were noticed in specimens under report.

5. Lipoid degeneration or fatty degeneration of the liver.

Lipoid degeneration, which in itself is a serious disease, has been observed to cause exophthalmia or protrusion of the eye-balls (Davis, 1937, p. 69). Diseased fish are darker in colour and float restlessly at the surface. The gills, due to a marked anæmia, are lighter in colour. The stomach and intestine contain little, if any, food and are filled with a pale yellow fluid. The body cavity is frequently distended. The striking characteristic is the condition of the liver which is light yellow or yellowish grey. The colouration may be uniform, but not infrequently the liver gets covered with dark blotches scattered at intervals. According to Davis this disease is mainly confined to Rainbow Trout.

The *post mortem* examination of the specimens revealed that the viscera were highly loaded with fat. In one case the liver was slightly yellowish, while in the other two it was light yellow, excepting the region near its point of attachment which was blackish. The size of the gall bladder was normal in the male, while it was enormously distended in the two females. The fluid in the gall bladder was found to be condensed into small, yellowish green masses. The variability in the size of the gall bladder noticed in the Harwan specimens is not, as remarked by Davis, an unusual occurrence.

The stomachs and intestines of the specimens were almost empty. In one female the intestine contained greasy fluid of a yellow colour condensed into fat-like globules. The mesenteries of the stomach, intestine and its cæcæ were heavily loaded with fat.

Though the colour is not well preserved in these specimens, the body appears generally darker. It may be noted that Brigadier Ross referred to the black colour of the body and the anæmic

condition of the mucous membrane in the mouth as the symptoms of the disease. As indicated above, these two symptoms are highly characteristic of the disease caused by a fatty degeneration of the liver (Davis, 1937, p. 69).

In view of the above it seems probable that the pop-eye condition in the affected Rainbows was induced by the lipid or fatty degeneration of the liver, due to the replacement of normal glycogen in the cells by a large accumulation of fat or lipoids. The fat, when in great excess, may also get deposited over various organs, as noticed in these specimens. The accumulation of too much fat normally results from malnutrition, but from the data supplied by Brigadier Ross there would appear 'nothing apparently wrong with the fish given as food'. It is, however, probable that the country fish from the Dal Lake, comprising species of *Crossochilus*, *Botia*, and *Schizothorax*, were rather rich in fat as most of them breed in the summer months. No definite data are available about the food and nutrition value of these species but as their local names indicate they are regarded highly fatty and slightly bitter in taste especially *Crossochilus*. Normally this type of fatty food may not affect healthy fish, but, as has been detailed below (*vide infra*, p. 402), the trout were living under unhealthy conditions in 1934 and this may have been responsible for their assimilating too much fat in their livers.

The injuries to the lenses noted above are in all probability accidental and may have been caused during the handling of the fish by the catchers. Brigadier Ross reported that the eyes were first protruded, but this condition later subsided. In this connection reference may be made to Bullin (1913, p. 634), who, quotes Hoffer's remarks that in the case of fish weakened by disease or in a dying condition the organs of sight are deeply sunk in their orbits whereas in healthy fish the eyes somewhat protrude and that incipient corneal opacity may sometime be taken as a diagnostic feature of graver disorders. For opacity he gives concussion as the chief cause, and remarks that the aqueous humour accumulates more in the anterior chamber resulting in the bulging out of the cornea. He has also indicated that the perforation of the cornea is largely due to the susceptibility of the fish, already weakened by disease, to injury. He is further of the opinion that in trout it may be due to their living in waters impregnated with iron. In the Harwan Hatchery iron screens are used in the pens, but there is the least probability for this factor as a causative agent owing to the fact that cases of trout with perforated cornea are very rare and that same screens and water are used for other fish which do not get affected. This may be an additional factor, but requires further investigation.

Edges of fins ragged and turned white.—The next point in Brigadier Ross's description of the disease relates to the edges of the fins getting ragged and turning white.

Of the three specimens examined, the large mature male with secondary sexual characters fully developed, has both the jaws injured. The lower portions of the caudal, anal and pelvic fins are

also injured. In the other two specimens, both of which are mature females, the jaws and the anal fins are only slightly injured, but the caudal fins are greatly damaged. From the nature of the injuries it seems probable that this is the result of sexual excitement. The injuries to the fins must have resulted from rubbing against the bottom of the pens preliminary to spawning.

The growth of fungus is usually accelerated by temperature and unhygienic conditions. Injuries of the type noted above, form suitable nuclei for the attack of fungus in fishes living under artificial conditions that prevail in hatcheries. From such focii the fungus later spreads to other living tissues.

As according to Brigadier Ross's report the pens at Harwan Hatchery were silted up to a depth of six inches, there is every probability that the resulting insanitary condition of the pens was in some way responsible for the ragging and fraying of the fins. In this connection reference may be made to the observations of Major Pyper, Residency Surgeon, who visited the hatcheries and examined fresh specimens. His examination of the ulcerated fins did not reveal any infection even under a high power of microscope, and it can, therefore, be safely concluded that the injuries to the fins were due, in the initial stages at least, to mechanical causes.

Large white marks below the gills.—Brigadier Ross also noted the presence of white marks below the gills. An examination of the specimens shows that there are a number of white spots or patches due to injuries over the body of the male specimen. Microscopic examination of scrapings from these patches did not reveal any type of infection.

Dr. Hora on receiving the specimens marked the white areas, which were in his opinion attacked by *Saprolegnia*, with white rings in the male specimen (Plate fig. 3). Though there is no evidence in the preserved specimens of the fungus in these regions I have personal experience of fungus causing considerable damage to trout in the Harwan Hatchery, Kashmir.

GENERAL CONSIDERATIONS AND CONCLUSION.

From the nature of the material it seems reasonable to assume that the injuries to the fins and other parts of the trout had probably been caused by sexual activities. The presence of ripe males and females in the same pen, and over-crowding may have been additional contributory factors. Occasionally injury is also caused by the netting of the fish for stripping manipulation or sale. Further, under favourable weather conditions any small injury may be sufficient for the *Saprolegnia* to attack fish.

According to Davis (p. 63), there is no evidence to show that fungus grows on healthy specimens unless there is some foreign organic matter adhering to the surface, while it develops quickly on dead and injured parts. Rushton (1935, p. 52) is of opinion that an excessive number of fish in an area results in causing abrasions and loss of scales which allow the fungus to get a hold.

Further, the presence of fungus is an indication of organic pollution. According to Brigadier Ross silt, probably containing organic debris, had accumulated from 3-6 in. deep in the pens at Harwan, and the pens were also over-stocked. For example, the affected ponds Nos. 4 and 5 with dimensions of 48 ft. by 5½ ft. by 5½ ft. and 46 ft. by 5½ ft. by 5½ ft. held 95 and 45, 3-4 and 4-5 years old fish respectively in 1934. Owing to drought there was shortage of water in the pens for several months preceding the epidemic. According to Major Pyper, filth had accumulated round the village over and above the hatchery during the earlier part of 1934, and with the onset of rains after March, this was washed into the stream and later into the pens.

It may also be pointed out that pen No. 5, which was most affected, is located at a place where the water is deepest and the current relatively much slower. In consequence the maximum amount of silt is collected in this pen. In pens Nos. 9 and 10, which held Brown Trout, on the other hand the water flows at so rapid a rate that any food thrown in at the upper end, if not ingested by the fish immediately, is carried to the lower end. It was probably for this reason that the Brown Trout were least affected.

Brigadier Ross further wrote that the disease attacked the males more virulently than the females. As has been explained above the males, under the urge of sexual excitement, are liable to receive more injuries and wounds during sexual combats than the females. Further, it is the males that struggle most while the milt is being taken out, and often slip off and get injured. Regarding the observation that it was the bigger trout among which the maximum rate of death occurred, while yearlings and 2-year old ones were apparently immune, it may be stated that here again the sexual maturity of the larger specimens explains the difference. Further, young fish, as a general rule, possess greater vitality, vigour and health. Another curious feature of the disease was that Brown Trout of the same age in the same hatchery had not been affected. This may be due to the fact that fatty degeneration of the liver, as noted by Davis, is confined to Rainbows only, while Browns are practically immune from it.

It may be concluded that whereas lipid disease is a result of malnutrition, food was not the only factor responsible for the epidemic; for the fish had already been weakened by adverse environmental conditions such as low water, overcrowding and unhygienic conditions of the pens. The malady was aggravated by the breeding season during which all reserves are used up for the proper development of the sexual glands. The sexual combats and efforts at spawning caused injuries to the fish and the then unhealthy condition of the pens made the fish liable to extensive attacks by fungus.

RECENT CASES OF MORTALITY.

In June 1938, Sir Peter H. Clutterbuck, Chief Conservator of Forests, Kashmir, was requested to send cases of Rainbow Trout

mortality in the Harwan Hatchery, Kashmir, in order to verify the data already available for the investigation of an epidemic among Rainbows in 1934. Accordingly, the Game Warden sent a collection of two Rainbows and one Brown Trout, each two years old, without any remarks regarding the circumstances of their death. As a result of *post mortem* examination, symptoms of fatty degeneration of the liver were observed in the two Rainbows, while the Brown Trout appeared to be a case of malstripping.

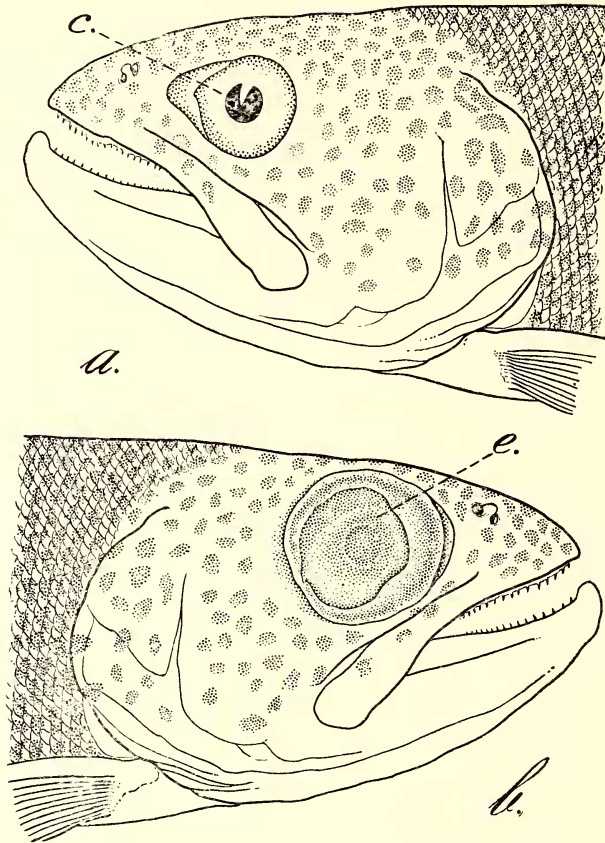
Fatty degeneration of the liver.—An external examination of one of the Rainbow specimens, 245 mm. in standard length, showed that it was somewhat blackish in colour and had a mark of an injury, with loss of scales and skin, over the posterior portion of the pectoral fin above the lateral line. These injuries seem to be the result of netting or other mechanical causes. The right eye appeared to be quite normal, but the left showed marked protrusion or exophthalmia. Internally a great deposition of fat in the mesenteries and along the entire length of the alimentary canal was observed. The liver was yellow with dark blotches on its outer border. The rest of the organs were normal, except the kidneys that appeared blackish in colour. The air-bladder contained fat globules. The dissection of the abnormal eye showed that the opaque cornea was greatly thickened by a deposition over it of a tissue-like matter which could be removed by means of a fine pair of forceps. According to Bullin (1913, p. 636) aqueous humour accumulates in large quantity in the anterior chamber and results in the bulging of the cornea outwards.

The second rainbow, 240 mm. in standard length, was more blackish in colour. The right eye was enormously enlarged and protruded (text-fig. 1 b). On dissection it was found that the lens had moved much forward, and almost touched the cornea. There were indications of fatty deposits in the eye-ball. The left eye, though normal in size, had a perforated cornea and the eye was without its lens. The perforation of the cornea (text-fig. 1a), according to Bullin (1913, p. 634), results from the existence of fish in waters impregnated with iron from drains, or from injury. The former, however, cannot account for the defective eye of a trout in the Harwan Hatchery as such cases are very rare and the fish as a rule do not suffer from such defects. In the present specimen, however, the pressure of fat from behind, as is characteristic of the disease, has probably thrown out the lens bursting out the cornea, for in the right eye, as observed already, there is still indication of the forward position of the lens and deposition of the fat in the posterior chamber.

An internal examination of the viscera revealed almost the same symptoms as noted in the first case, except that the liver had degenerated and was greatly reduced in size. The amount of fat deposited was in excess of that observed in the previous specimen. The stomach and intestine were empty.

In my opinion the fatty degeneration of the liver may have been caused by feeding the fish on fatty diet, as already indicated in the foregoing account. The diet of the fish is reported to be the

same as it has ever been, but from my experience of the Harwan Hatchery I know that trout are fed on country fish from the Dal Lake belonging to the genera *Crossochilus*, *Botia* and *Schizothorax*. During summer when species of *Schizothorax* are not easily available in the Dal, *Botia*, and *Crossochilus* form the bulk of the food-supply.



Text-fig. 1.—Lateral views of head and anterior part of body from the left and right sides of a Rainbow Trout that died in the Harwan Hatchery, Kashmir in 1938. *Nat. Size.*

a. Showing perforation (*c*) of the cornea of the left eye; *b.* Showing enormous protrusion (*e*) of the right eye.

No definite data are available regarding the food value of these forms but according to the general belief in Kashmir they are regarded as highly fatty; their local names *teth-garh* or 'bitter fish' and *tel-garh* or 'oil fish' are to a certain extent indicative of their food value. Another factor that may have caused this mortality is the low temperature. According to Gaschoot (1929), low water temperature is very favourable to the outbreak of the fatty degeneration of the liver. The specimens under report were received in November when the hatchery water is very cold. According to Davis, the disease is confined to Rainbows only.

Malstripping.—The specimen of Brown Trout, 220 mm. in standard length is a 2-year old female. An external examination showed the presence of a large number of white patches on the body. A prominent feature was the presence of an ovum at the mouth of the genital opening held in position by a cup shaped sheath protruding out from the genital aperture (Plate I, fig. 2). The posterior half of the left pectoral fin was missing, and almost all the other fins were considerably frayed (Plate I, fig. 1).

Internally the ovaries were found to be fully developed and contained mature ova still held intact in the ovarian follicles. The ovarian membrane was slightly injured a little above the position of the vent and so was also the peritoneum.

From the above it would appear that an effort had been made to extrude the eggs forcibly before they had become loose and fallen into the body cavity; this operation seems to have resulted in the extrusion of only one egg, inflicting at the same time injuries to the ovarian membrane and the peritoneum. Similar cases of malstripping have been noticed by me (in press) from the Hatcheries of the Kagan Valley, Hazara District. The white patches noticed on the skin may be due to a fungus attack, but a microscopic examination of scraping from these regions did not reveal any parasitic infection. The missing portion of the left pectoral fin seems to have been nibbled off by a stronger trout. Frayed condition of the fins, especially of the caudal (Plate I, fig. 2), is clearly noticeable. According to Rushton (1937, p. 358), the fins become frayed when the fish are kept under insanitary conditions.

SUMMARY.

From an examination of the material in the collection of the Zoological Survey of India the author discusses an epidemic that broke out among Rainbow Trout in the Harwan Hatchery, Kashmir, in 1934. He further makes observations on certain recent cases of mortality from the material obtained from the same hatchery in 1938. A short description of the material and the results of the *post mortem* examination are given.

The epidemic is traced to lipoid or fatty degeneration of liver, which was probably caused through feeding the fish on fatty diet. Normally the disease would have never occurred in the form of an epidemic but it was accentuated owing to unfavourable conditions that prevailed for several months preceding the epidemic. These were—shortage of water, insanitary conditions of the pens and over-crowding that resulted in abrasions, and subsequent attack by fungus. The malady was further aggravated by the breeding season when the vitality of the fish is naturally reduced as the epidemic was noticed just at the close of the breeding season.

The recent cases of Rainbow mortality corroborate the observations made in connection with the fatty degeneration of the liver in the cases of mortality of 1934. In the case of Brown Trout death has been attributed to malstripping, while the frayed condition of the fins was probably due to unhygienic conditions of the pens.

NOTE ON THE 1934 EPIDEMIC AMONG RAINBOW TROUT IN THE HARWAN HATCHERY, KASHMIR, BY BRIGADIER A. CAMPBELL ROSS.

1. The Hatchery was inspected by the Game Warden (Major Anchal Singh) on the 1st April, 1934 when everything was correct and as far as we know no signs of disease.

2. From 1st to 15th April . . . 13 'Rainbow' had succumbed; on 16th four were sick, on the 17th two fresh cases developed; and all six of these died on the 17th and 18th April making a total of 19 casualties from 1st to 18th April.

3. Total stock of Rainbow in all Pens in the Hatchery is as follows:—

85 Cock fish.
25 Hen fish.

130 total. (These fish are all of over 2 years; excluding yearlings and younger fish.)

4. The death among the 'Rainbow' according to age and sex are as follows:—

No.	Date of death.	No. of tank.
2 Cocks	3-4-1934	5
1 Cock	5-4-1934	5
2 Cocks	5-4-1934	4
1 Hen	5-4-1934	5
2 Cocks	6-4-1934	4
1 Hen	8-4-1934	4
1 Cock and } 1 Hen	9-4-1934	5
1 Cock	10-4-1934	4
1 Hen	13-4-1934	5
2 Cocks	17-4-1934	5
2 Hens	17-4-1934	4
1 Cock	18-4-1934	4
1 Hen	18-4-1934	5

	Weight.	Approximate age.
Cocks 2.	5 lbs	5-6 years.
4.	4 lbs	3-4 years.
1.	3½ lbs	3-4 years.
4.	3 lbs	3 years.
1.	2½ lbs	3 years.
Hens 1.	4½ lbs	4-5 years.
1.	4¼ lbs	4-5 years.
1.	4 lbs	3-4 years.
1.	3½ lbs	3-4 years.
1.	3 lbs	3 years.
2.	2½ lbs	3 years.

5. The proportion to sex among the casualties is:—

12 Cocks to 7 Hens.

The disease appears to attack the older fish as nearly all the yearlings and 2-year olds so far appear to be immune.

Description of Disease.

Taken from a Hen 'Rainbow' fish (age 3 years and weight 3 lbs.) when sick for five days. She died on the 7th day.

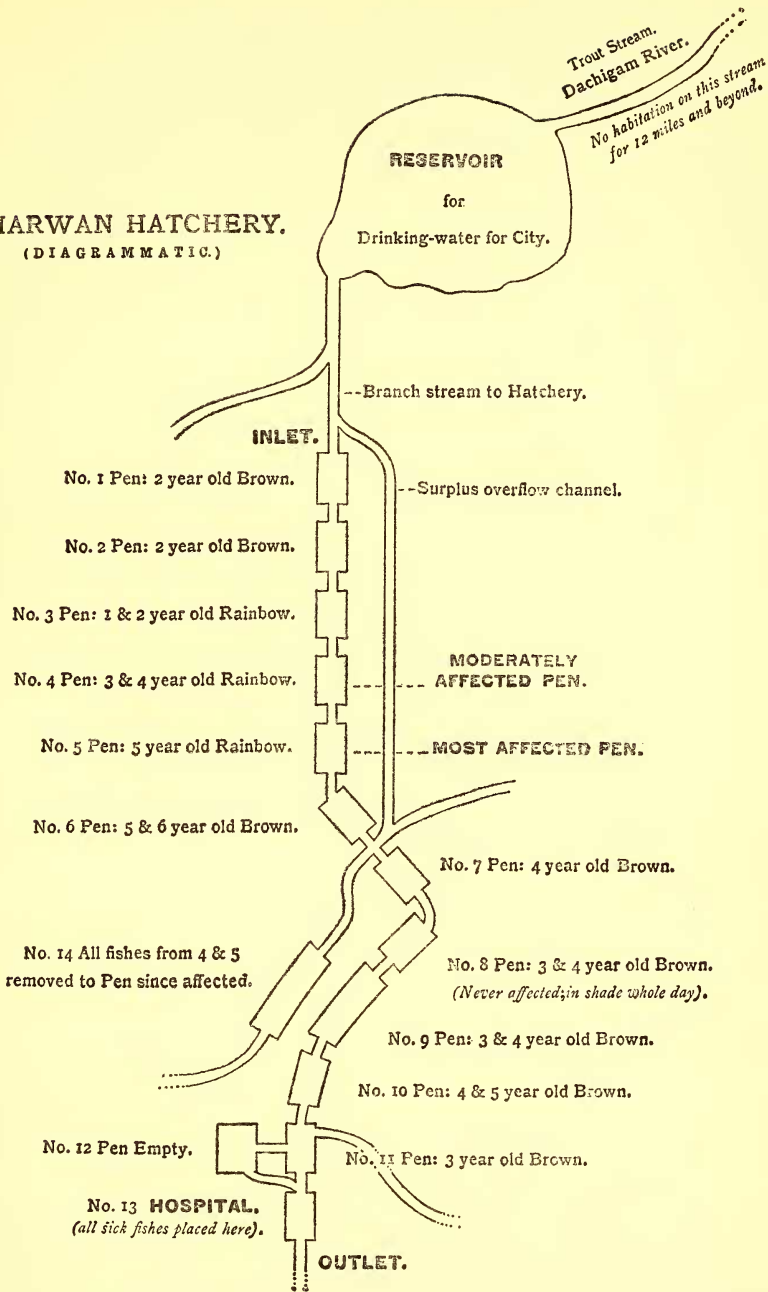
- Very bulging eyes covered by a white opaque film, like very severe cataract. This is the principal feature of the disease—the eyes at first protrude right out of the socket; then get covered by the opaque film after which the eye subsides to normal.
- Edges of fins ragged and discoloured. Edges turned white.
- Large white marks below the gills.
- Mucous membrane inside the mouth white and very anæmic.
- Stomach discoloured and whole body turning blackish.

Other data.

Water.—

- Source. There is no change in the source of water supply, which has been the same since the establishment of the Hatchery over 30 years ago; the channel of the water course being the same,

HARWAN HATCHERY.
(DIAGRAMMATIC.)



A rough plan of the Harwan Hatchery.
(Supplied by Brigadier A. Campbell Ross.)

